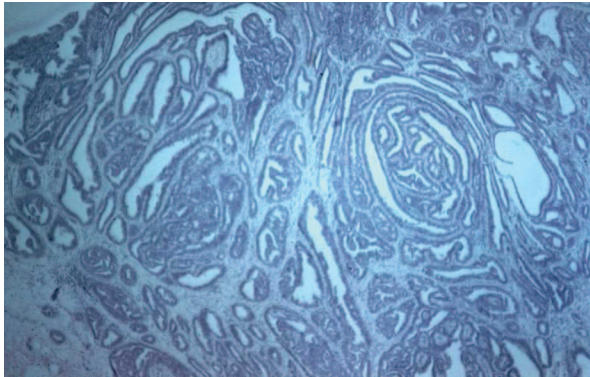


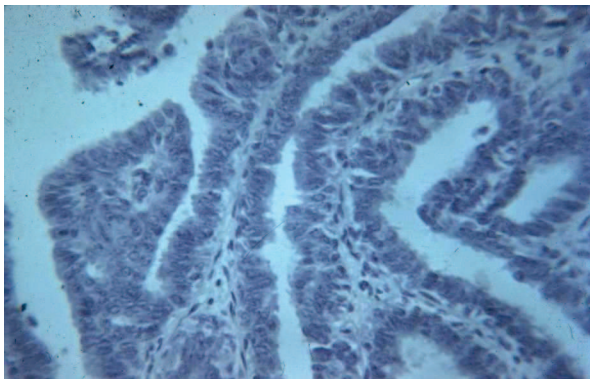
## Hidradenoma



At first glance, appears malignant

Benign uniform epithelium

No mitotic figures



## HPV, Intraepithelial neoplasia and squamous cell carcinoma

These sections are similar to, and are covered in the section on cervix.

*Remember: generally speaking: vulva is the same as vagina and cervix except that there is a layer of keratin on the surface. Exception: Rete pegs are more common on vulva, but these are lost in lichen sclerosis*